

Ophthalmology Times

Research Scholar

Honoree Program

Progression to Surgery for
Epiretinal Membranes with
Good Vision

November 9, 2017



UBM



UBM

FINANCIAL DISCLOSURES:

None



MY ROLE IN THIS RESEARCH:

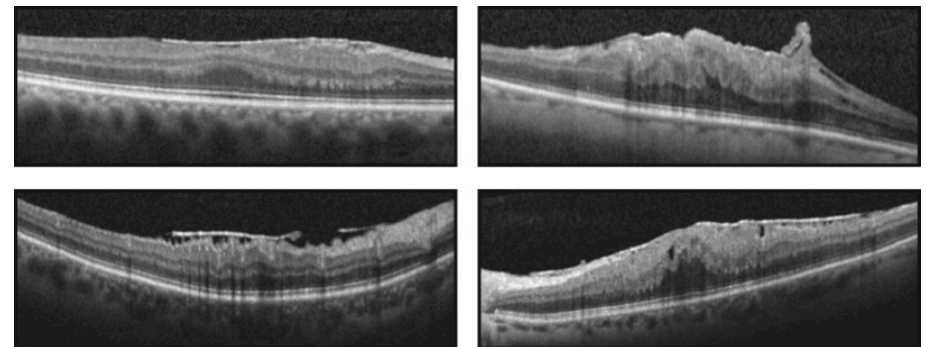
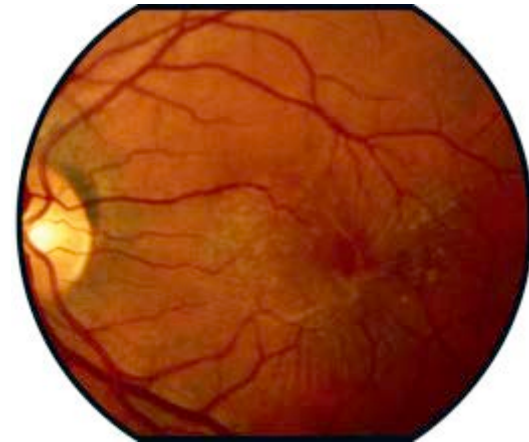
Please answer which of the following portions of the research you participated in:

- X Conception and design of the work/project
- X Acquisition of data
- X Analysis and interpretation of data
- X Creation and/or critical review of the presentation



Epiretinal membrane (ERM)

- Sheet-like fibroglial membranes over the inner surface of macula
 - Idiopathic
 - Secondary
- Visual symptoms
 - Asymptomatic
 - Decreased vision, metamorphopsia, diplopia
- ERM present in 30 million adults in the United States 43 to 86 years old.¹



1. Klein R et al. Transactions of the American Ophthalmological Society 1994



Management for ERM

- Observation
- Pars plana vitrectomy (PPV) with membrane peel
 - Overall, successful in improving vision but final vision often imperfect
 - Complications: cataract, retinal breaks (<1.5%), retinal detachments (<1.5%) and endophthalmitis (<0.05%) with small gauge PPV¹
- Traditionally, PPV reserved for intolerable symptoms and poor vision
- Recently, PPV done for symptomatic good vision eyes²⁻⁵
 - Compared with poor vision eyes: smaller visual gain, but better absolute vision following surgery

1. Folk et al. Ophthalmology 2016
2. Reilly G et al. Retina 2015
3. Thompson JT. Retina 2005
4. Lehpamer BP. Retina 2015
5. Moisseiev E. Curr Eye Res 2016



Management for ERM

- Deciding when to operate?
 - **Operate:** Intolerable symptoms (symptoms worse than visual requirements for every day activities)
 - **Observe:** Asymptomatic
 - **Unknown:** Tolerable symptoms

Clinical question: For patients referred to a retina practice who have currently have tolerable visual symptoms for their everyday activities, what is the risk of progression to intolerable symptoms?



Natural History of ERM

- **The Blue Mountain Eye Study¹**
 - 3654 eyes: ERM progressed (28.6%), regressed (25.7%), and remained stable (38.8%) by stereo fundus photos at 5 years
- **Byon et al²**
 - 62 eyes with VA \geq 20/40: 9.7% had decreased vision, 6.5% had improved vision at 24 months

1. Fraser-Bell S et al. Ophthalmology 2003.
2. Byon IS et al. Ophthalmologica 2015.



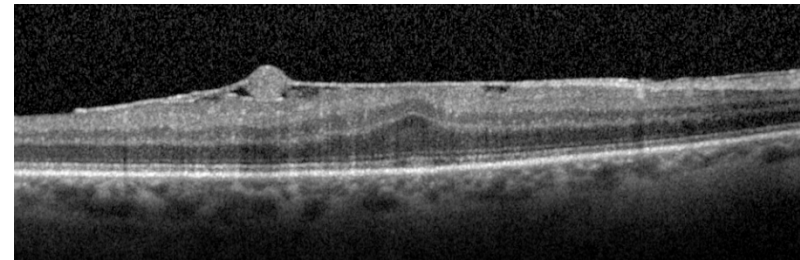
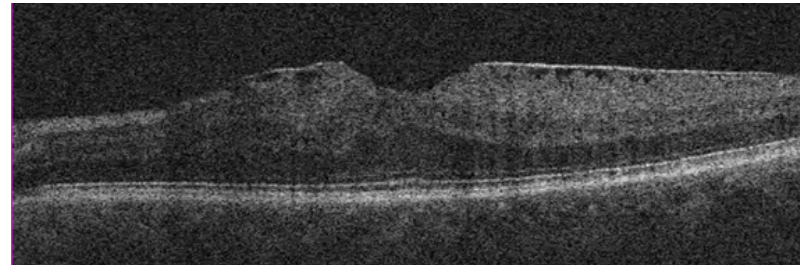
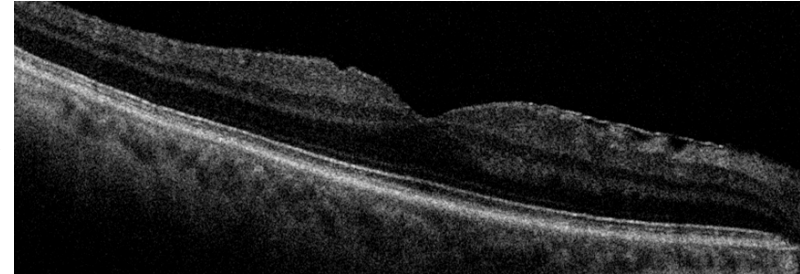
Study Design

- Retrospective
- Inclusion Criteria
 - New diagnosis of idiopathic ERMs 20/40 or better and no intolerable visual symptoms
 - 2009 and 2012
 - 5 surgeons in retina practice
- Exclusion Criteria
 - Absence of baseline and/or final OCT
 - Lamellar hole, vitreomacular traction
 - Eye with other ocular pathologies: macular degeneration, retinal vascular diseases, amblyopia, severe glaucoma, high myopia greater than 6D, retinal detachment/tears, vitreous hemorrhage, history of intraocular surgery other than cataract, limiting corneal pathology
- Primary outcome measure
 - Time to visual acuity 20/50 or worse and/or intolerable visual symptoms attributable to the ERM (demonstrated worsening on OCT), leading to surgery



Study Design

- Categorized by baseline OCT morphology
 - Normal foveal contour
 - Mild loss of foveal contour
 - Loss of foveal contour
- **Goal:** quick recognition by surgeon and patient





Results

- 107 eyes from 99 patients
- Age 66 ± 10 years

| | n | Baseline VA |
|------------------------------------|----------|-------------|
| Overall | 107 | 20/27 |
| Normal Foveal Contour | 24 (22%) | 20/26 |
| Mild Loss of Foveal Contour | 26 (24%) | 20/25 |
| Loss of Foveal Contour | 57 (53%) | 20/29 |



Results

- 107 eyes from 99 patients
- Age 66 ± 10 years

| | n | Baseline VA |
|------------------------------------|----------|-------------|
| Overall | 107 | 20/27 |
| Normal Foveal Contour | 24 (22%) | 20/26 |
| Mild Loss of Foveal Contour | 26 (24%) | 20/25 |
| Loss of Foveal Contour | 57 (53%) | 20/29 |



Results

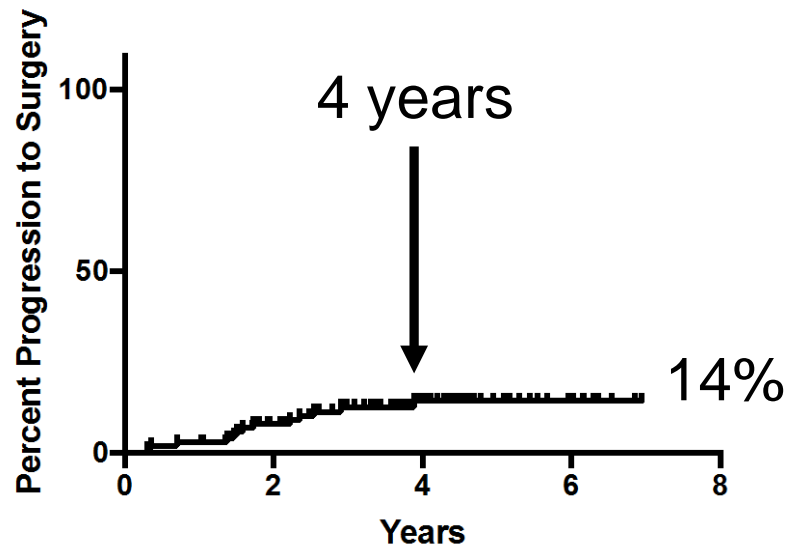
- 107 eyes from 99 patients
- Age 66 ± 10 years

| | n | Baseline VA |
|------------------------------------|----------|-------------|
| Overall | 107 | 20/27 |
| Normal Foveal Contour | 24 (22%) | 20/26 |
| Mild Loss of Foveal Contour | 26 (24%) | 20/25 |
| Loss of Foveal Contour | 57 (53%) | 20/29 |



Results

Kaplan Meier Curve for Progression to Surgical Membrane Peel For All Eyes

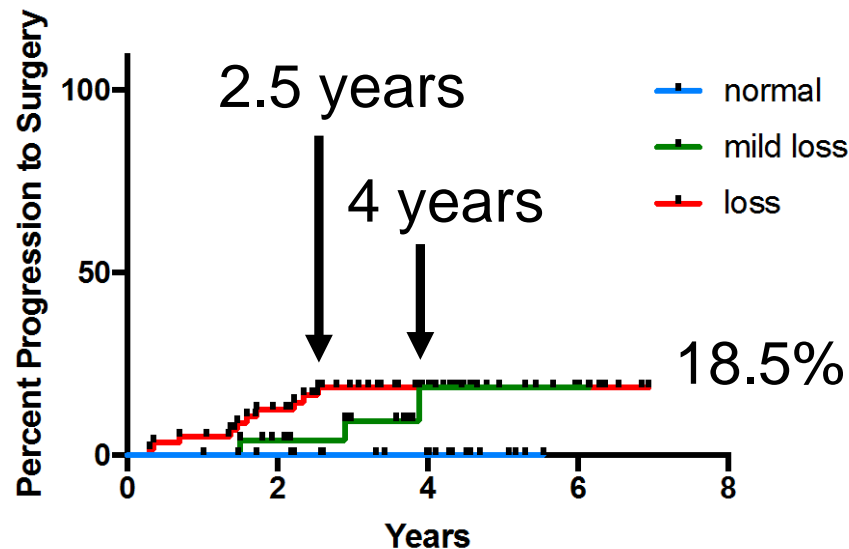


- 14% of ERMs became sufficiently symptomatic for surgery at 7 years
- No eyes progressed to surgery after 4 years



Results

Kaplan Meier Curve for Progression to Surgical Membrane Peel by Baseline OCT Morphology

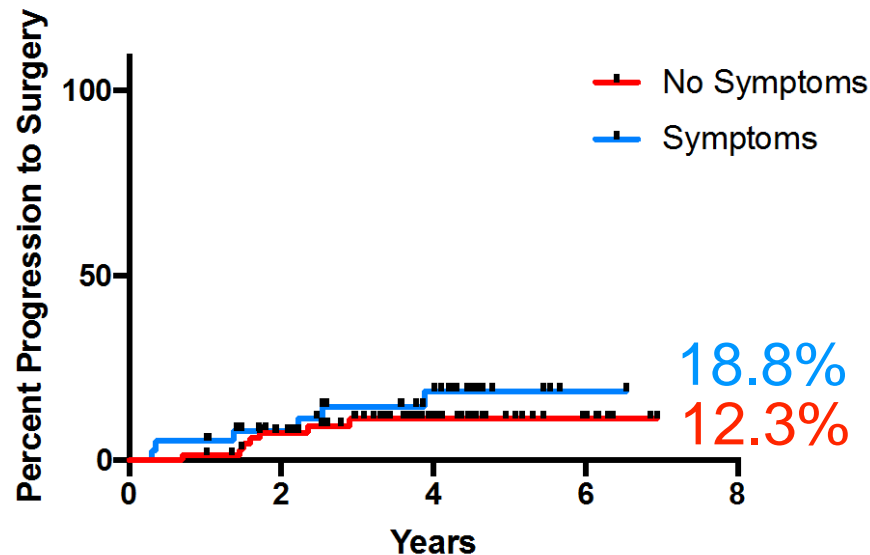


- Eyes with **normal foveal contours** did not progress to surgery at 5.5 years
- 18.5% of eyes with **mild loss of foveal contour** and 18.5% of eyes with **loss of foveal contour** progressed to surgery by 7 years
 - Eyes with **loss of foveal contour** progressed faster than **mild loss of foveal contour**



Results

Kaplan Meier Curve for Progression to Surgical Membrane Peel by Presence of Symptoms



- Symptoms = blurry vision, metamorphopsia, diplopia
- 18.8% of eyes **with symptoms** progressed to surgery
- 12.3% of eyes **without symptoms** progressed to surgery
- $p = 0.34$



Limitations

- Retrospective nature
- Best-available vision maybe worse than best-corrected visual acuity
 - Our study would over-estimate progression rate
- Referral bias to retina clinic
- Surgeon bias to discussion with patient
- However, real-world data



Summary Points

- 14% of ERMs referred to retina practice with good vision became sufficiently symptomatic for surgery at 7 years
- Progression of ERMs with good vision is associated with baseline OCT morphology
 - No eyes with normal foveal contours progressed to surgery at 7 years
 - ERMs with complete loss of the foveal contour progresses more rapidly than incomplete loss of foveal contour; however, the curves converge at 4 years
- Eyes with baseline symptoms did not have a statistically different progression to surgery as eyes without symptoms



UBM

Thank you

- xuejingchen3@gmail.com



Appendix

Subtitle



Results

- 107 eyes from 99 patients
- Age 66 ± 10 years

| | n | Baseline VA | Follow-up Duration |
|------------------------------------|----------|-------------|--------------------|
| Overall | 107 | 20/27 | 3.8 ± 1.5 |
| Normal Foveal Contour | 24 (22%) | 20/26 | 3.6 ± 1.4 |
| Mild Loss of Foveal Contour | 26 (24%) | 20/25 | 3.5 ± 1.4 |
| Loss of Foveal Contour | 57 (53%) | 20/29 | 3.9 ± 1.5 |